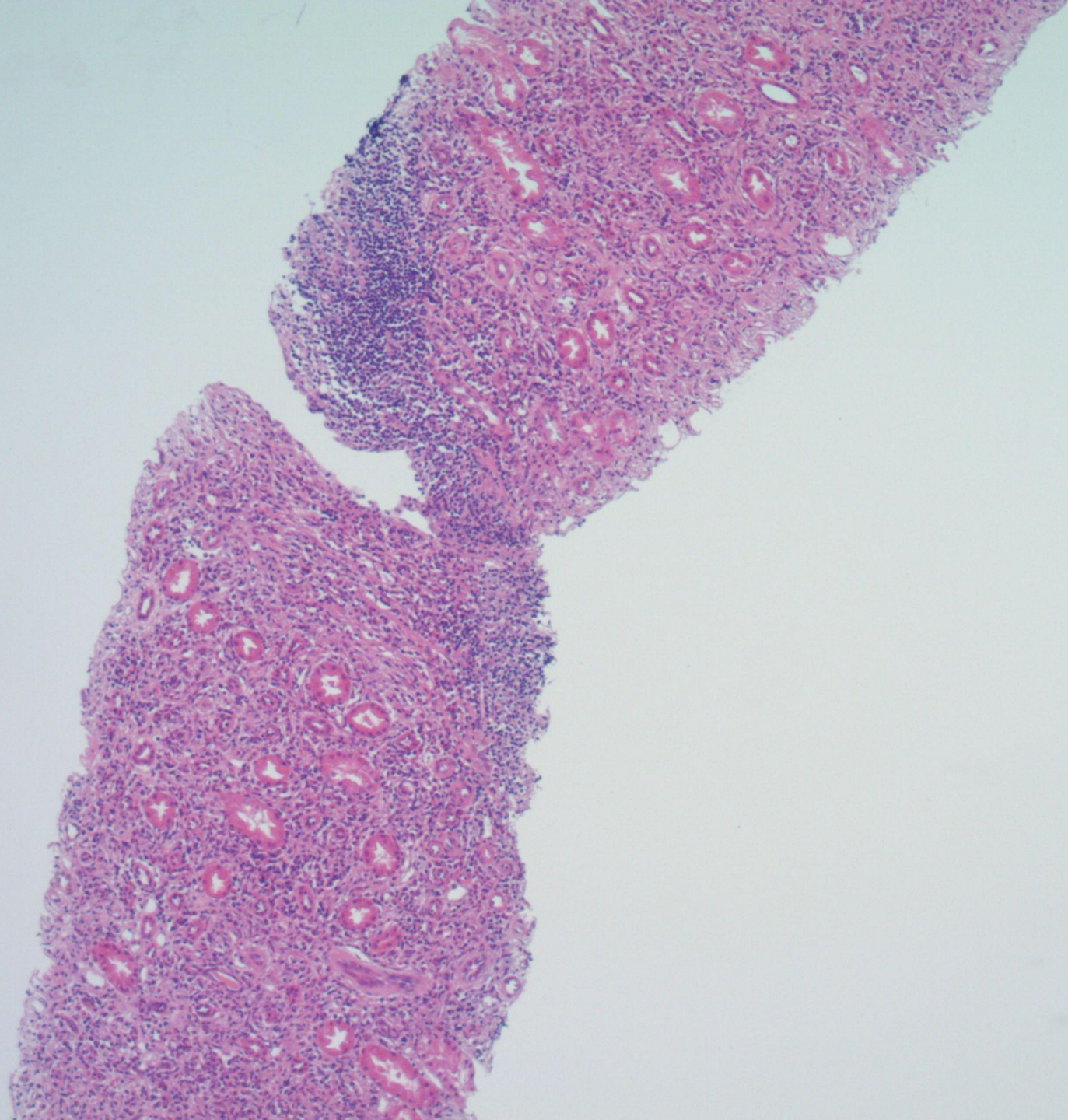
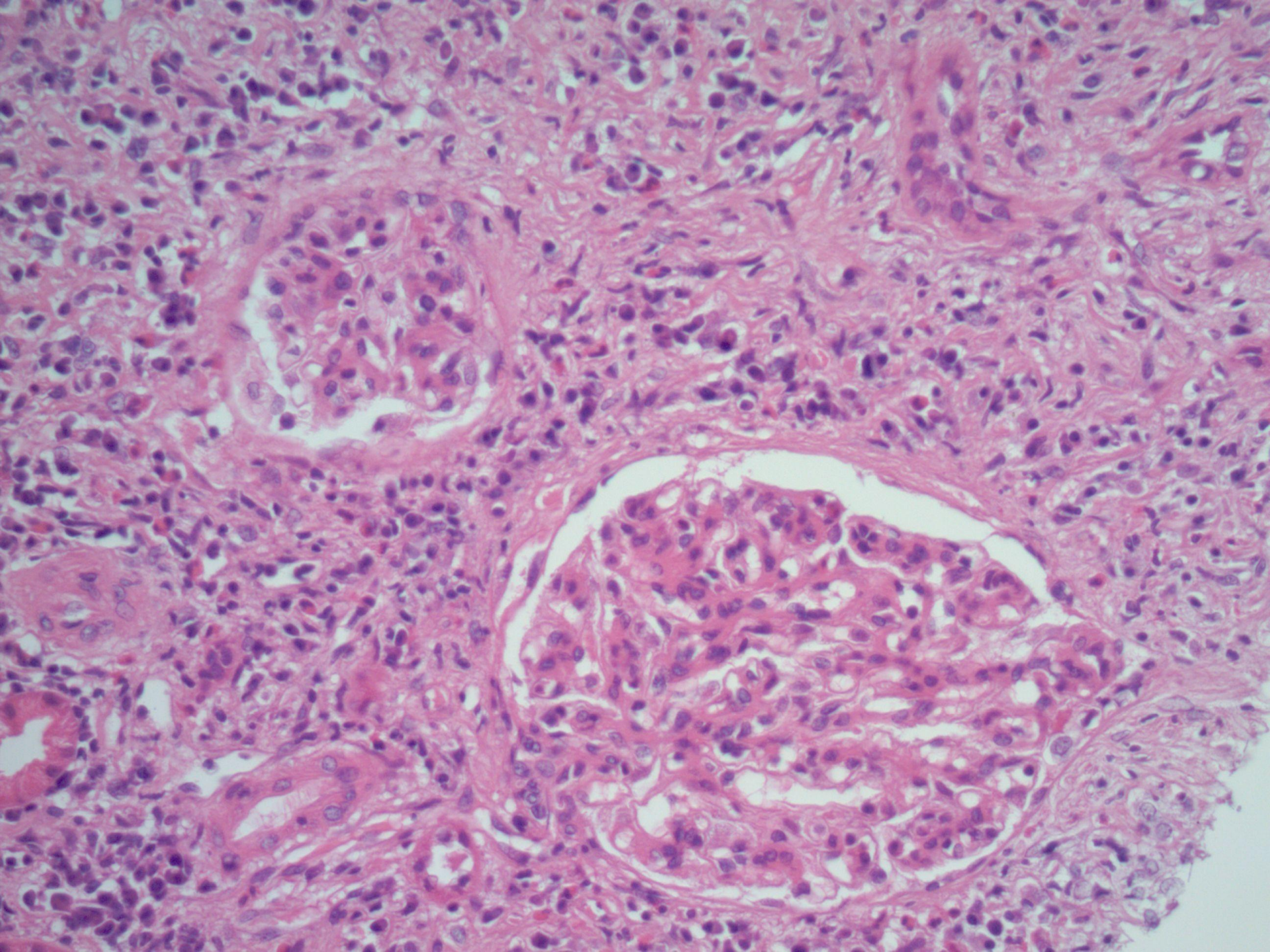
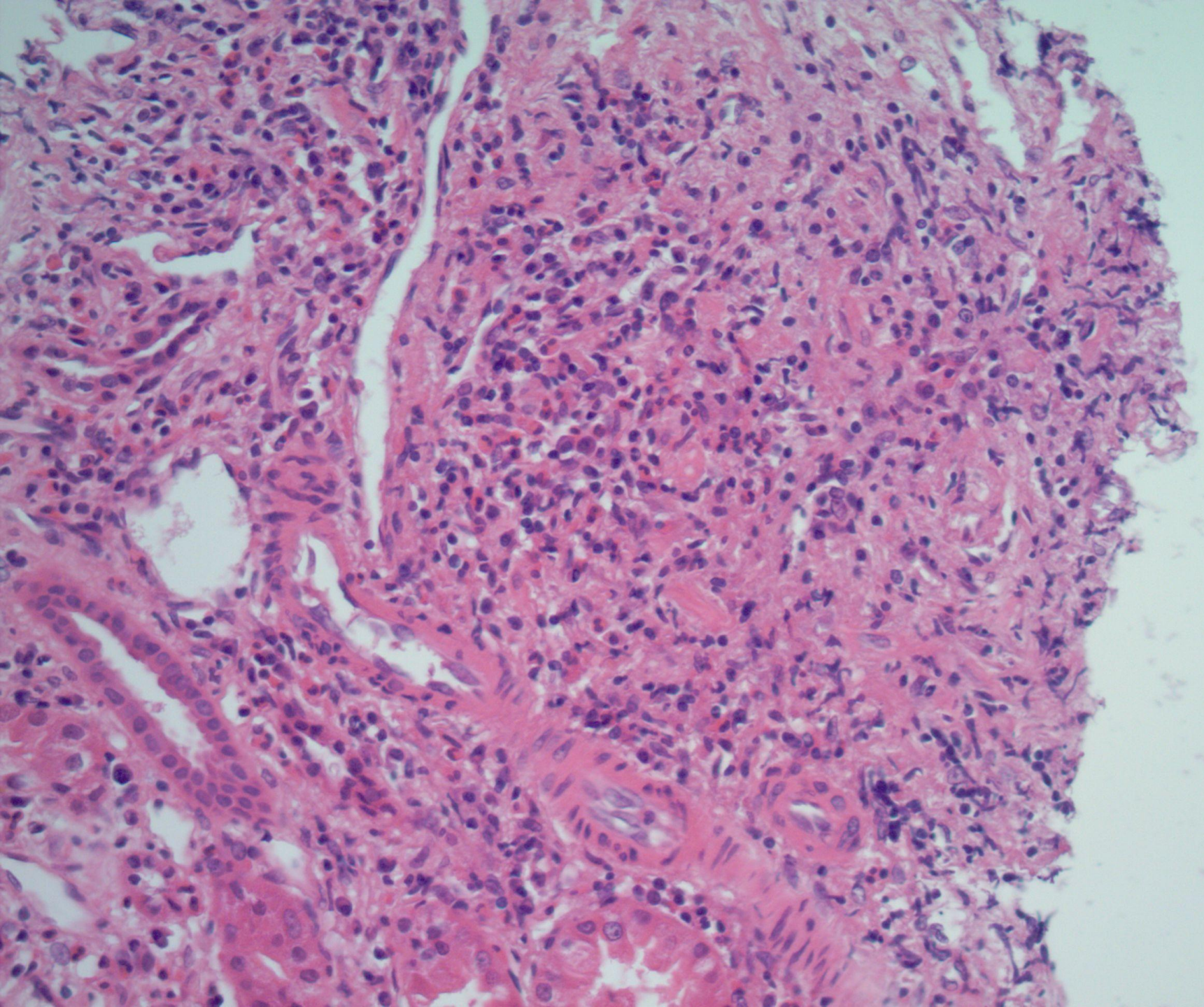


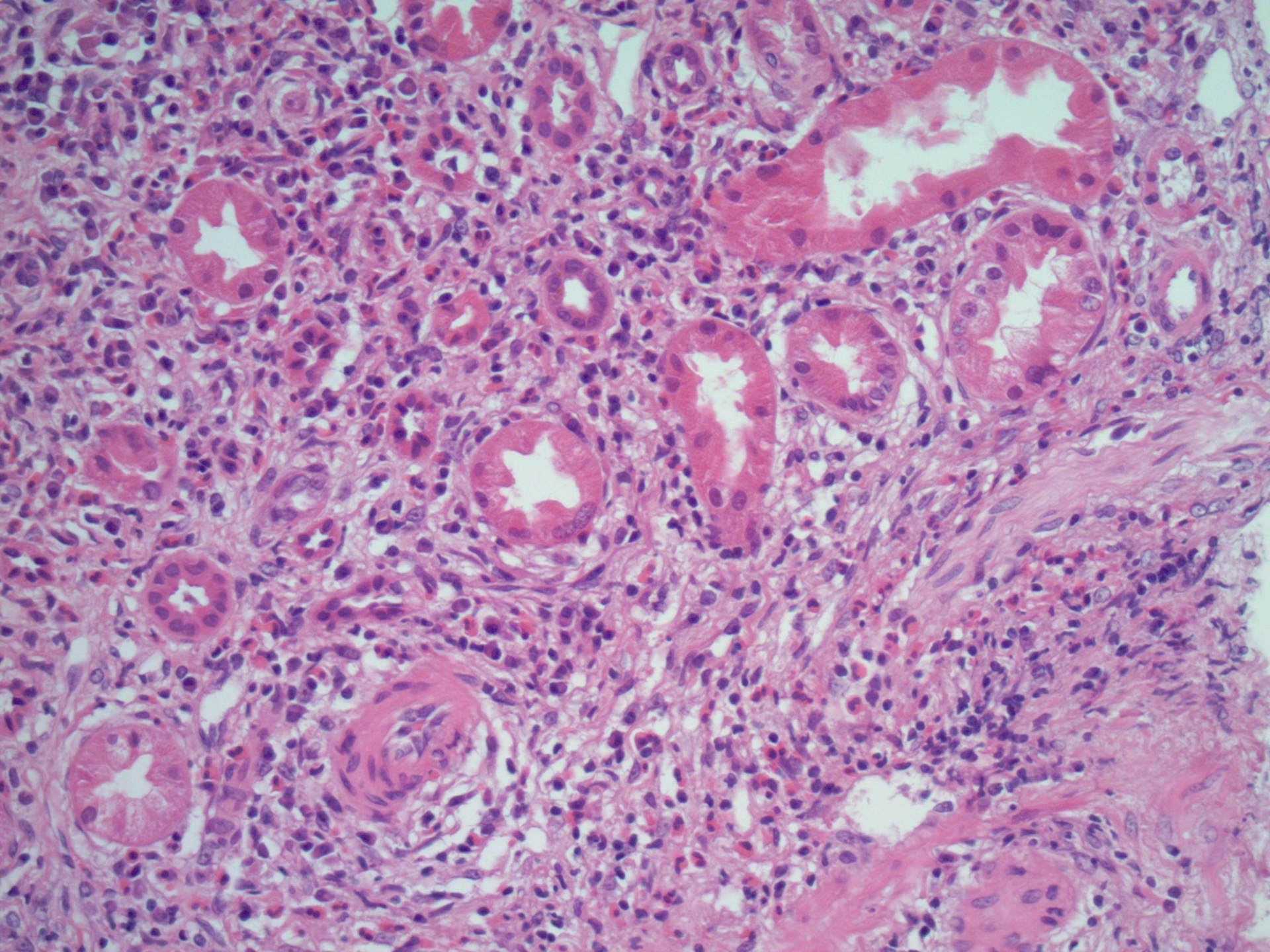
Case 12

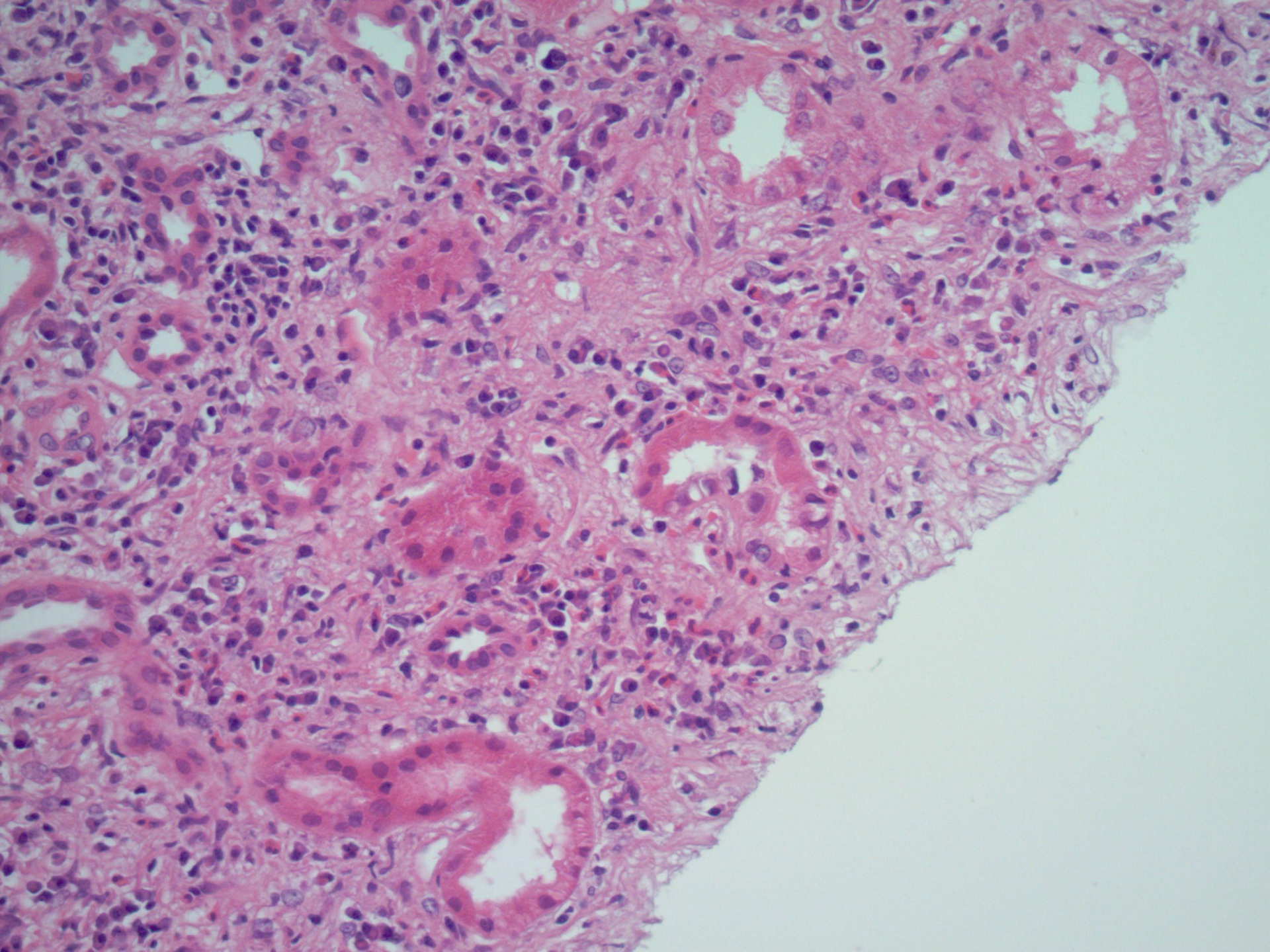
- Male aged 50.
- Vasculitic rash and diarrhoea.
- Creatinine 207, PCR 122
- Eosinophil count 7
- Haematuria.

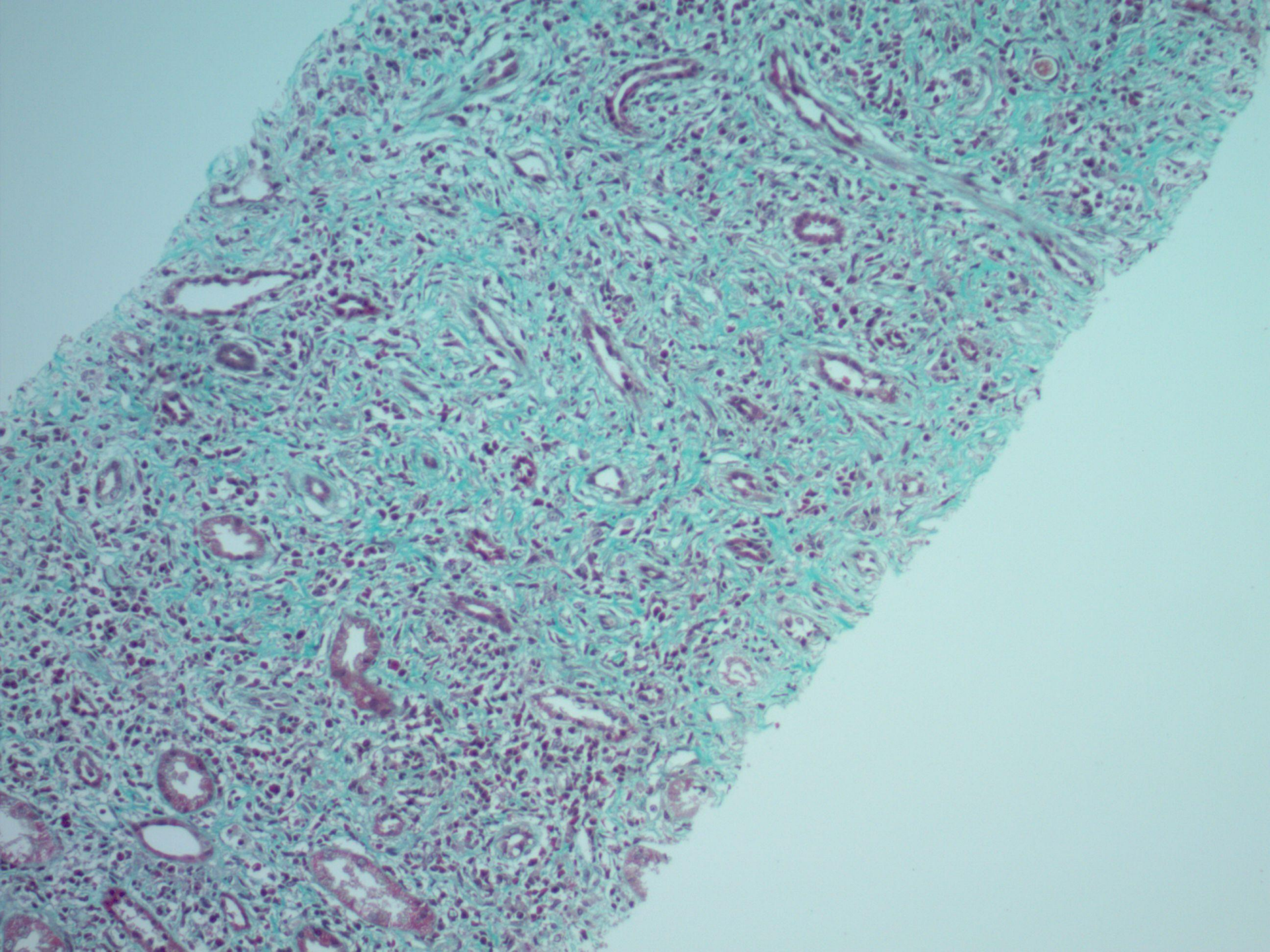








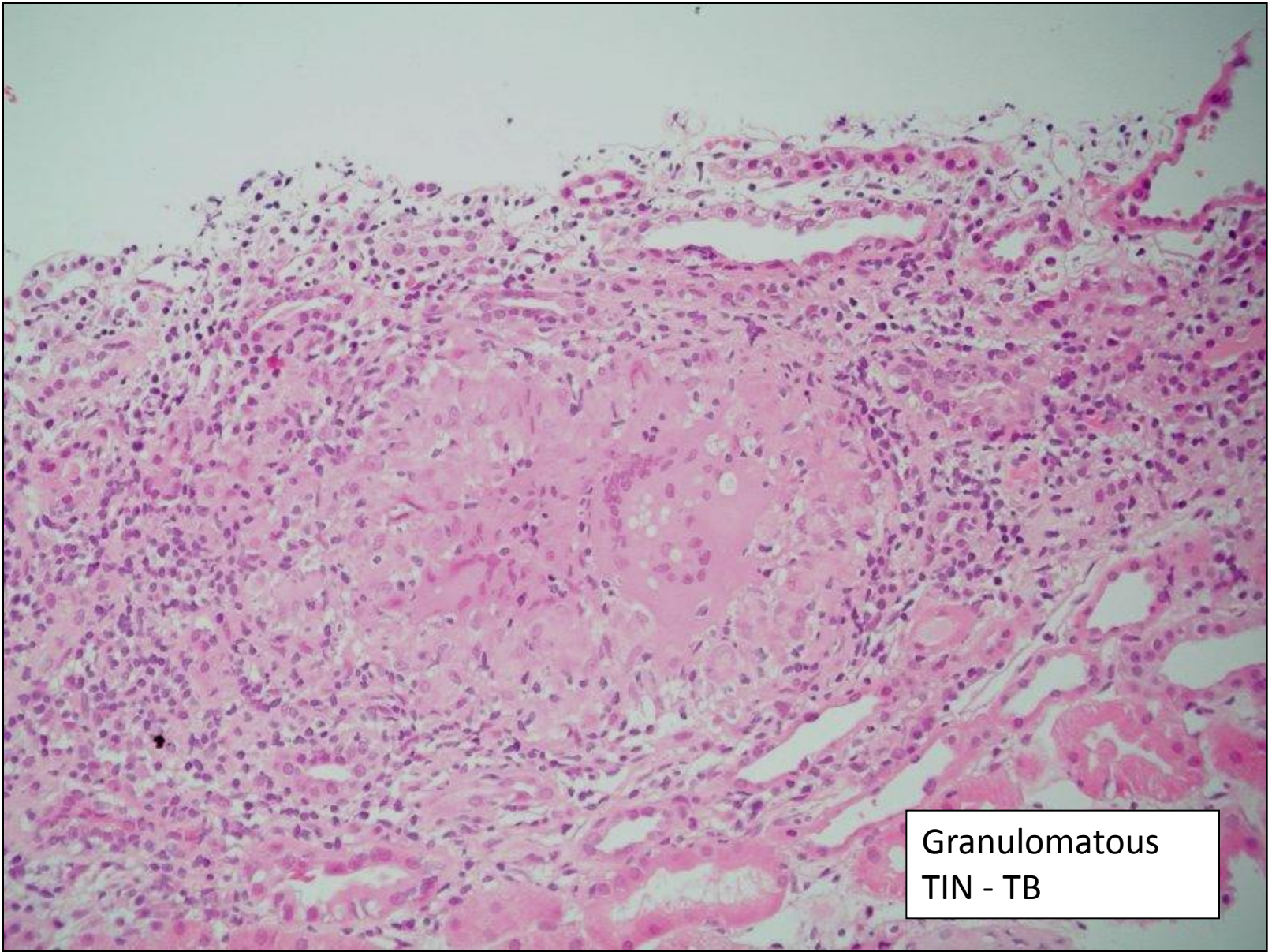




- What is the diagnosis?
- What other diagnoses are possible?
- What do you want to do to investigate further?

Tubulo-interstitial nephritis

- wide range of toxins and drugs
- acute allergic TIN
- granulomatous TIN



Granulomatous
TIN - TB